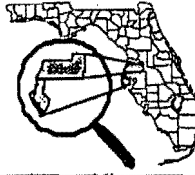


MEDICAL EXAMINER
District Six

Pasco & Pinellas Counties



10900 Ulmerton Road
Largo, FL 33778
727-582-6800
(Fax 727-582-6820)
www.pinellascounty.org/forensics

REPORT OF AUTOPSY


Name: [REDACTED] Case #: 5140066 Age: [REDACTED] Race: White Sex: Male
Investigating Agency: Pasco County Sheriff's Office Agency Case #: 14-01529
Date of Death: January 13, 2014 Date of Examination: January 14, 2014 at: 1212 hrs.

AUTOPSY FINDINGS:

1. Intermediate range grazing gunshot wound of right hand/wrist
2. Penetrating gunshot wound of chest

Cause of Death: Gunshot wound of chest

Manner of Death: Homicide


Jon R. Thogmartin, M.D.
Chief Medical Examiner

Date: 01/23/14



Accredited by the National Association of Medical Examiners

REPORT OF AUTOPSY

2 of 3

NAME: [REDACTED]

CASE NUMBER: 5140066

EXTERNAL EXAMINATION: The body is that of a 205 pound, 76 inch, white man who appears the recorded age of [REDACTED]. The scalp is covered in short brown hair. The eyes are hazel and no petechiae are noted. The mouth has natural dentition. A plastic tube is in the mouth. The ears and nose are not remarkable. Chest tubes are in both chest cavities. Defibrillator pads are on the body. EKG pad is on the body. IV lines are in the upper extremities. An intraosseous line is in the left shin. The skin of the back is intact, and the spine appears straight. An ID band is on the left wrist. The anterior portion of the body has trauma to be described below. An intravascular line is in the left side of the neck. A small beard is on the chin. The external genitalia are circumcised and partially shaved. A few faint hypopigmented scars are on the right shin. A few faint linear and punctate scars are on the knees. The right hand has injuries to be described below. Needle sticks are in the left antecubital fossa.

EVIDENCE OF RECENT TRAUMA: A gunshot wound is on the left side of the chest at a location 16 ½ inches below the top the head, 7 ½ inches below the level the shoulders, and 1 ¼ inches to the left midline. The wound consists of a 1.2 x 1.2 cm somewhat triangular perforation with a somewhat square shaped, 0.5-1 cm abrasion margin on the left side. At the 10 o'clock margin the wound on the skin of the central chest is a 1.2 x 1 cm abrasion and this is located approximately 1.5 inches from the gunshot wound entrance wound. The wound path passes through the soft tissue of the chest, perforating the 4th intercostal space and left 4th rib, perforates the pericardial sac, and perforates the heart through the right ventricle and right atrium. In the base of the heart a yellow metal bullet jacket is recovered. The projectile core continues exiting the heart and perforates the right lower lung lobe terminating in the posterior midportion of the right lower lung lobe. At the termination wound path is a lead metal deformed fragment.

The gunshot wound is associated with blood in the pericardial sac along with residual blood in the chest cavities. There is soft tissue hemorrhage in this in the chest. The right lung contains blood in the airways and alveoli. Also associated with the gunshot wound is diffuse anterior and posterior mediastinal hemorrhage.

The bullet is directed front to back a distance of ~ 5 ½ inches.

A gunshot wound is on the lateral surface of the right wrist and consists of 2 x 3.5 cm somewhat obliquely oriented graze gunshot wound with tears directed anteriorly and tags directed posteriorly. The wound transects some of the soft tissue and grazes the extensor tendons of the right index finger. No bone is perforated. The wound has surrounding stippling on the posterior surface of the hand. The wound is directed back to front when the arm is in the anatomical position.

Note: The paths of the two gunshot wounds correspond when the right hand/wrist is held in front of the thorax and likely represent the path of a single bullet.

INTERNAL EXAMINATION: The muscles of the chest and abdominal walls have injuries previously described. The pleural cavities are smooth. The left pleural cavity has a focal adhesion. The diaphragm is intact.

REPORT OF AUTOPSY

3 of 3

NAME: [REDACTED]

CASE NUMBER: 5140066

NECK: The soft tissue of the anterior portion the neck has an area of hemorrhage. Plastic tubes are in the esophagus and larynx. The cervical spine is intact. The larynx is light tan and coated in food material.

GASTROINTESTINAL SYSTEM: The stomach is normally located and light. The tan The small and large bowels are tan green and unremarkable. The small and large bowels are tan green and unremarkable. No adhesions are noted. The appendix is not remarkable. The bowels have no perforations. The stomach has intact green tan mucosa with no petechiae or ulceration. The esophagus has pink tan unremarkable proximal mucosa.

ENDOCRINE SYSTEM: The pancreas is tan, lobular, and unremarkable. The left adrenal gland is brown and unremarkable. The right adrenal gland is yellow brown and unremarkable. The thyroid gland is right light brown and appears unremarkable.

HEMOLYMPHATIC SYSTEM: The spleen is 340 g and appears unremarkable. The parenchyma is soft and red. The bone marrow of the ribs is not remarkable. No enlarged lymph nodes are noted.

MUSCULOSKELETAL SYSTEM: The muscles are normally developed without degeneration or atrophy.

CARDIOVASCULAR SYSTEM: The heart is 390 g and has a normal shape. The heart is perforated from a gunshot wound previously described. The aorta has minimal atherosclerosis. The coronary arteries are normally developed with minimal atherosclerosis.

RESPIRATORY SYSTEM: the right and left lungs are 470 and 450 g respectively. The outer surfaces are red purple with scattered anthracotic macules. The lungs have no tumors. The lungs have trauma previously described. The hilar lymph nodes are somewhat anthracotic. The parenchyma of the lungs has moderate anthracosis.

HEPATOBIILIARY SYSTEM: The liver is 2410 g and is an intact transparent unremarkable capsule. The gallbladder contains 3 mL of green yellow bile without stones. The brown/red parenchyma is not remarkable.

GENITOURINARY SYSTEM: The testicles are palpable in the scrotal sac. The urinary bladder is unremarkable. The prostate gland is not enlarged. The right and left kidneys are 200 and 220 g respectively. The outer surfaces are brown and smooth. The corticomedullary ratios and pelvic fat are not remarkable. No collecting systems stones are seen.

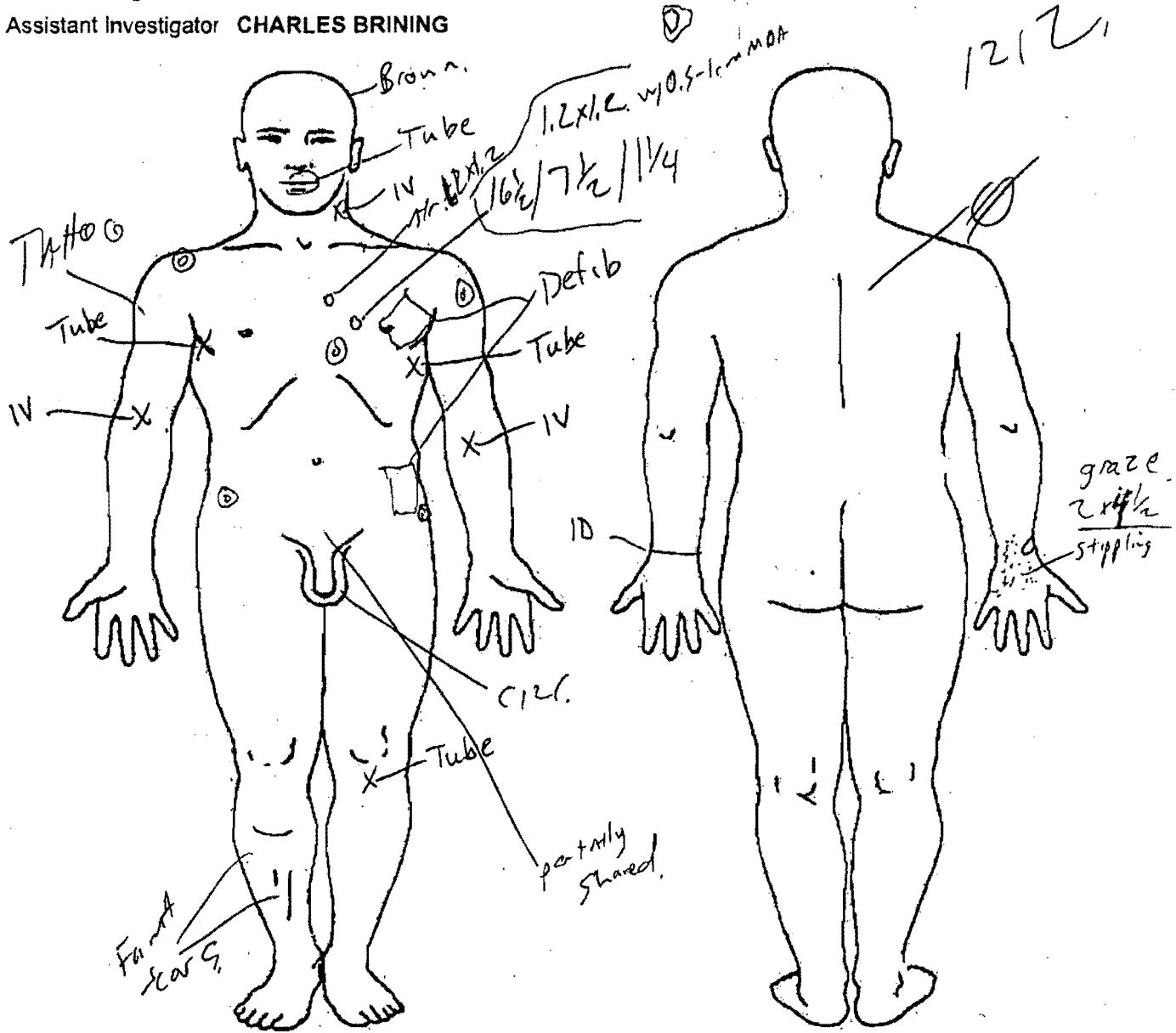
CENTRAL NERVOUS SYSTEM: The scalp, skull, and 1490 g brain are not remarkable. The sulci and gyri are not remarkable. The cranial nerves are not remarkable and the arteries at the base of the brain are not remarkable. No abnormalities are noted in the cortical gray or white matter, midbrain, cerebellum, pons, or medulla.

**MEDICAL EXAMINER
District Six**

Pinellas & Pasco Counties

Autopsy Sketch

Case Number **5140066** Decedent **[REDACTED]**
 Date of birth **[REDACTED]** Age **[REDACTED]** Sex **Male** Race **W**
 Hair Color **Brown** Eye color **Brown Hazel** Weight **205 LB** Height **76 IN**
 Date of death **01/13/14** Time of death **14:17** Exam date and time
 Case Pathologist **JON R. THOGMARTIN, MD, ME**
 Case Investigator **DUSTIN DAILEY**
 Assistant Investigator **CHARLES BRINING**



<u>390</u> Heart	<u>450</u> L. Lung	<u>340</u> Spleen	<u>220</u> L. Kidney	<u>400</u> Urine
<u>470</u> R. Lung	<u>2410</u> Liver	<u>200</u> R. Kidney	<u>1490</u> Brain	<u>150</u> Gastric

**MEDICAL EXAMINER
District Six**

Pinellas & Pasco Counties

Evidence Release Sheet

Case Number 5140066

Decedent [REDACTED] Race: W Sex: M Age: [REDACTED]
Pathologist JON R. THOGMARTIN, MD, ME Investigating Agency Pasco County Sheriff's Office
Investigator DUSTIN DAILEY Agency Case Number 14-01529
Asst. Investigator CHARLES BRINING
Date/Time Death 01/13/2014 14:17

All items were delivered sealed in envelopes or bags:

Sexual Assault Swabs

- Vaginal
- Oral
- Rectal
- Other

Other:

Fingernail Clippings:

- Right Hand
- Left Hand
- Gunshot Residue:
 - SEM Stubs

Hair Standards:

- Head
- Pubic
- Arm
- Other _____

Blood Standards:

- FTA Dried Spots
- Red Top Tubes(s)
- Purple Top Tubes
- Other _____

~~one sealed yellow paper envelope containing " Buccal Swab "~~
~~one sealed clear plastic bag containing "Photo ID"~~
~~one sealed yellow paper envelope containing "Projectile fragments from chest"~~
LAST ITEM

Released By: Thogmartin Agency: MEU Released To: Veronica Lambert Agency: MEU
(Print Name) (Print Name)
Signature: [Signature] Date: 1-14-14
Signature: [Signature] Date: 1-14-14
Released By: J. Timms Agency: MEU Released To: FLT S. Miller Agency: PASCO
(Print Name) (Print Name)
Signature: [Signature] Date: 1.15.14
Signature: [Signature] Date: _____
Released By: _____ Agency: _____ Released To: _____ Agency: _____
(Print Name) (Print Name)
Signature: _____ Signature: _____ Date: _____

REPORT OF INVESTIGATION

Name: [REDACTED]
Investigator: Dustin Dailey

Case#: 5140066
Date: January 13, 2014

Summary:

The death reported to this office was that of [REDACTED] a [REDACTED] old white male shot by other person(s). The decedent was a patron at the Cobb Theatre in Wesley Chapel when a verbal altercation escalated and the decedent was shot in the chest by a .380 caliber Kel Tec handgun. The decedent was transported from the scene to Florida Hospital Wesley Chapel where he was pronounced dead in the Emergency Room. The Pasco County Sheriff's Office is the investigating agency and has assigned case number 14-01529.

Narrative:

At about 1445 hours on January 13, 2014 I was contacted by Emergency Room staff at Florida Hospital Wesley Chapel reporting the death of [REDACTED] a [REDACTED] old white male. The decedent was transported from the Cobb Theatre in Wesley Chapel, 6333 Wesley Chapel Loop where he was reportedly shot by other person(s). The decedent was coded on scene and on his trip by ambulance to the hospital. The decedent was worked, but they were unable to regain a pulse. The decedent was pronounced dead at 1417 hours by Dr. Cottrall.

I contacted Det. Proctor of the Pasco County Sheriff's Office who advised the following information. The incident occurred at about 1328 hours. The decedent and his wife were at the theatre getting ready to watch Lone Survivor. The decedent was reportedly texting during the previews for the movie. The male suspect in the case was sitting behind the decedent with his companion. The male suspect repeatedly asked the decedent to stop texting. The male suspect went to complain to the manager of the theatre who went to talk to the decedent about not texting. The male suspect returned to his seat a verbal altercation occurred that escalated to the point where the decedent was shot by the male suspect. One round was fired from a Kel Tec .380 semi-automatic hand gun with serial number Ju135. The round apparently struck the decedent's wife's finger and his wrist and traveled into his chest. A Sumter County Deputy who was off duty secured the male suspect until Pasco County Sheriff's Office arrived. The decedent was transported from the scene.

The decedent was lying in a supine position on the hospital bed at Florida Hospital Wesley Chapel in the Emergency Department. The decedent was clad in white/red sneakers. The decedent's clothing had been removed. The decedent was intubated and observed to have chest tubes on the right and left sides of this chest. The decedent had IV sites in his right arm, lower left shin, right side of neck and upper right chest. The decedent was observed to have an open wound to the right wrist with observed stippling. The decedent was observed to have an open wound to the chest. The decedent was observed to have an abrasion to the chest near the open wound of the chest. The decedent was observed to have a [REDACTED] to the right arm. CSI Gonzalez performed finger nail scrapings/clippings at the hospital along with GSR and major case prints. The decedent was wearing a black metal watch and white/yellow metal ring on his left ring finger. The decedent's jewelry and clothing were collected by CSI Gonzalez.

The decedent was identified by Pasco County Sheriff's Office per his Florida DL. The decedent's next of kin was notified of the Medical Examiner's involvement in the case. Medical Examiner staff transported the decedent along with his chart to the Medical Examiner's office.

Dustin Dailey
Forensic Investigator